

# Evidence for Laser- and Light-Based Treatment of Acne Vulgaris

Girish S. Munavalli, MD, Mhs,\* and Robert A. Weiss, MD<sup>†</sup>

Acne is a very prevalent skin disorder, affecting more than 85% of adolescents and often continuing into adulthood. Active acne and its sequelae, especially permanent scarring, may cause longstanding psychological or emotional harm in patients. Novel and promising treatments with laser/light devices (such as blue light, red light, pulsed dye laser, infrared lasers, light-emitting diodes, and pulsed light) have been reported to have varying degrees of efficacy for treatment. The authors compiled a summary of evidence-based literature on laser/light treatment for acne to assist clinicians to more appropriately identify treatment options, should they choose to supplement current medical antiacne therapies.  
Semin Cutan Med Surg 27:207-211 © 2008 Published by Elsevier Inc.

Acne vulgaris is a common skin disease, affecting more than 85% of adolescents and often continuing into adulthood.<sup>1</sup> Active acne and its sequela, especially permanent scarring, may cause longstanding psychological or emotional harm in patients. Evidence suggests that the impact of acne on a patient's psychological and emotional well-being is comparable with that of chronic systemic disease processes such as diabetes, asthma, arthritis, and epilepsy.<sup>1</sup> Indeed, the aim of acne treatment should be to reduce the impact and existence of symptoms, including psychosocial sequelae of the disease.

Topical and oral medications, such as retinoids, benzoyl peroxide, macrolide antibiotics, and isotretinoin, are the mainstay of treatment for acne and rightfully given first consideration, based on severity of the disease. In the past decade, an increasing number of published studies have documented the clinical improvement in acne after sequential treatment with laser- and light-based devices. The rapid clearance of acne lesions, reported after device treatment, is particularly of interest to patients and physicians. As enticing as these modalities for antiacne management may be, a knowledge of evidence-based literature is helpful when entertaining treatment options. As a prelude to this, it is insightful to examine the impact of acne on quality of life on patients, as well as to discuss the possible intervention points in

the pathogenesis of acne where device-based treatments may be successfully used.

## Rationale

Quality-of-life measurements often are used to determine the severity of impact of a disease on an individual. Previous studies have suggested that acne affects the lives of adults in various ways, including their employment, social behavior, and body dissatisfaction.<sup>2</sup> For example, in a sample of 1250 subjects, Cunliffe<sup>3</sup> found that the unemployment rate was 7% greater for adults with acne. With regard to acne, 2 factors are reported to be uniquely significant. The first factor involves the severity of disease and varies from patient to patient. The degree of severity should be considered from both the physician and patient perspective. Only a few scattered lesions may seem trivial to the treating physician but may cause intense psychological distress to the patient. This distress should be recognized and not minimized during the evaluation. Research suggesting that more severe acne (as judged by the dermatologist) is more likely to be associated with psychological factors, such as anxiety, and with greater effects on patients' lives.<sup>2</sup> In another study, the psychosocial effects of acne on quality of life were found to be influenced more by patients' self-perception of their acne severity than by the objective severity of the disease.<sup>3</sup>

Closely related to this, the second factor involves the age of the patient. Although the overall prevalence of acne does decline with age in both sexes, a significant number of individuals experience either a worsening of acne symptoms or fail to experience improvement after their teenage years. Multivariate analysis has shown that the increasing age of afflic-

\*Dermatology, Laser, and Vein Specialists of the Carolinas, Charlotte, NC.  
<sup>†</sup>Department of Dermatology, Johns Hopkins University, Baltimore, MD.  
Address reprint requests to Girish Munavalli, MD, MHS, Assistant Professor of Dermatology, Johns Hopkins University, Director—Dermatology, Laser, and Vein Specialists of the Carolinas, PLLC, Charlotte, NC 28207.  
E-mail: gmunava@yahoo.com.

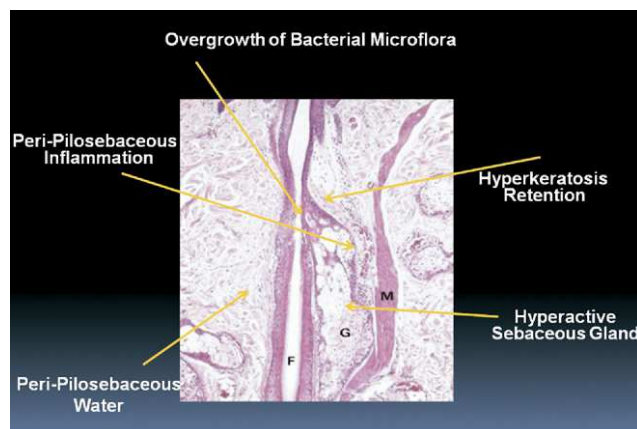
tion with acne can proportionately affect the quality of life.<sup>2,4</sup> In an aforementioned study, adults were asked what bothered them the most about having acne and stratified their answers by age.<sup>2</sup> Most patients responded that they were bothered by acne's appearance. Interestingly, appearance was most troublesome to patients aged 30 to 39 years. One explanation for this difference among age groups is that patients younger than 30 years are closer to adolescence and feel that acne is accepted by their peers, whereas those aged 40 years and older may have themselves accepted acne. Overall, these findings support the premise that patients are affected differently by acne during different stages in their lives.<sup>2</sup>

Although the clinical diagnosis of acne is usually readily made from examination, designing effective treatments for patients can be challenging. Conventional medicines are effective but have potential drawbacks, including patient compliance, side effects, potential induction of antibiotic resistance microbe, and longevity in terms of onset of action.<sup>4-6</sup> Patient variability is also an important factor to consider in efficacy. For example, patients with acne and extremely greasy skin tend to be less beneficially helped by oral or topical medications.<sup>5</sup> However, thorough discussion of the pros and cons of specific medical acne treatments is outside the scope of this article. Nonetheless, patient concern with untoward effects, coupled with a relative capability on the part of older patients (compared with younger patients) to pay out of pocket expenses for nonreimbursable device treatment for acne, has set the stage for an increased interest and willingness to undergo laser/light-based therapeutic approaches. Additionally, late adolescent and adult-onset acne provided a patient population with an extreme desire for rapid regression of acne lesions and with age and maturity level capable of tolerating more involved, office-based treatments.

Both medical and device treatments for acne should effectively target and suppress several key processes in the formation of acne for maximum benefit. Current research indicates that the pathogenesis of acne involves 4 key processes: follicular hyperproliferation, excess sebum production, inflammation, and proliferation of *Propionibacterium acnes*.<sup>1</sup> Postulated histologic targets of the dysfunctional pilosebaceous unit for laser/light intervention are highlighted in Figure 1.

Long ago, it was recognized that prolonged exposure to sunlight helps to clear acne-laden skin. Indeed, a favorite pastime of acne-afflicted adolescents is self-treatment by exposure to sunlight outdoors or indoors using tanning beds. Ultraviolet light contained in natural sunlight was postulated to be destructive to bacterial skin flora and to suppress inflammatory skin processes, although the exact role of this form of phototherapy was unclear.<sup>7</sup> Ultraviolet light with and without the application of psoralen was the first to be studied and showed mixed results, although the risks seemed to outweigh the benefits.<sup>7,8</sup>

More recently, visible light source devices have been evaluated and include both continuous wave and pulsed-light devices. The concepts for device treatment were made possible through an evolving understanding of laser-tissue inter-

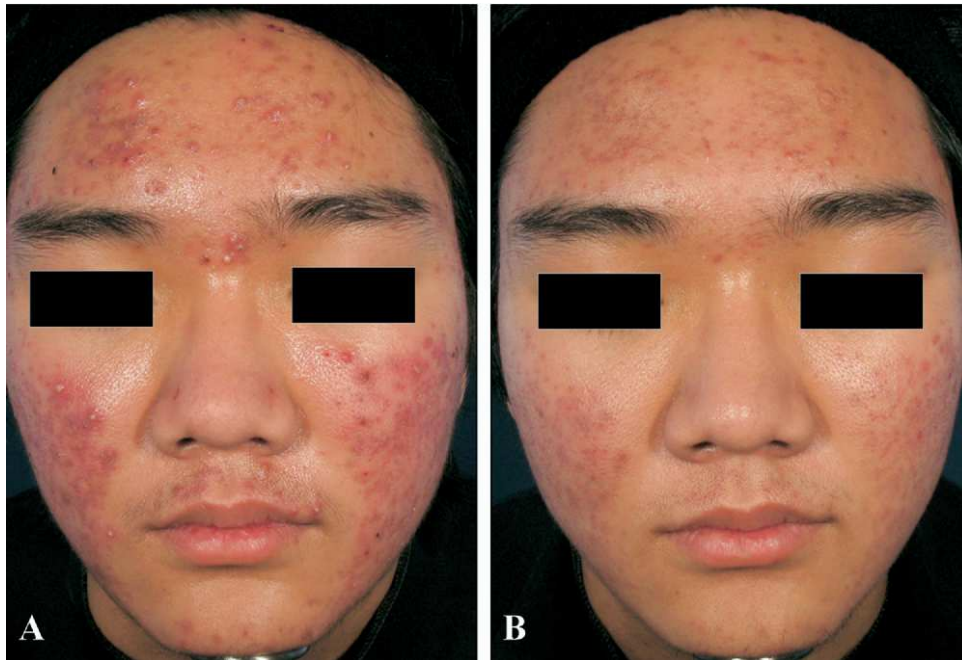


**Figure 1** Illustration of the pilosebaceous unit that identifies potential targets for intervention with laser/light device-based therapies.

action involving bacterial skin flora, porphyrins, and sebum and the development of a variety of new lasers, light sources, and radiofrequency devices.<sup>9</sup> Newer devices use combined techniques to treat acne. One such promising example uses photopneumatic technology, or vacuum suction delivered simultaneously with broadband-pulsed light and can induce rapid clearance of acne lesions. Figure 2 illustrates the degree of rapid clinical improvement in response to treatment with such a device. This technology has undergone recent clinical and histological review,<sup>10-13</sup> although the efficacy and longevity of clinical improvement has yet to undergo controlled clinical trials scrutiny. On the basis of years of clinical experience with device treatment for acne, the authors use an algorithm for approach to device-treatment based on subtype of acne lesions, always in conjunction with existing medical regimens for maintenance (Fig. 3).

Recently, several articles have concisely summarized the efficacy of different light/laser modalities of treatment.<sup>9,12-14</sup> These are reviewed in the following paragraphs. Ortiz and coworkers<sup>12</sup> in 2005 reviewed the laser treatments for acne, categorizing previous studies based on the effect on the specific target structure of the pilosebaceous apparatus. The 3 main categories centered around effects on (1) the sebaceous gland, (2) pilosebaceous microvasculature, and (3) bacterial overcolonization. They noted the promising efficacy of the 1450 nm diode laser for its thermal effects on the sebaceous gland secondary to absorption of heat from the target chromophore of surrounding papillary dermal water. They also noted the conflicting published results regarding the use of the 585 nm laser for acne and emphasized that the only randomized, controlled study showed no difference between treated patients and untreated controls with regards to lesion counts and sebum production.<sup>15</sup>

In another 2005 review, Ross<sup>13</sup> noted more than 20 devices alone that were cleared by the Food and Drug Administration in the United States for light-based acne therapy.<sup>12</sup> Ross rationally discussed the optics of light treatment for acne and focused on the limitations of certain light sources with and without adjuvant therapy, such as the use of aminolevulinic acid in the case of photodynamic therapy, in an attempt



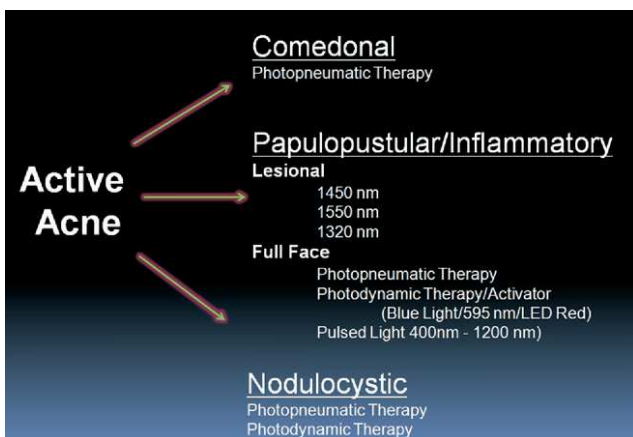
**Figure 2** A 16-year-old-male patient was treated by Dr. Girish Munavalli with 2 treatments of photopneumatic therapy (Isolaz, Aesthera, Inc, Pleasanton, CA), using a concurrent vacuum suction/broadband light source, with a 1-week interval in between treatments. (A) Before treatment and (B) 1 week after the second treatment.

to selectively destroy the target organ in the skin responsible for acne, the hyperactive sebaceous gland. Ross methodically reviewed commonly used wavelengths with an emphasis on their inherent ability to reach and selectively thermally injure the sebaceous gland and impact the dysfunctional acro-infundibular hyperkeratization process.

Mariwalla and Rohrer<sup>9</sup> also reviewed laser treatment options in 2005. Again, a distinction was drawn between the mechanism of action and reviewed studies were characterized along these lines. The authors provided a succinct and well-written evaluation of available options at the time but didn't comment on the quality of design or reproducibility of the studies they reviewed.

A more recent review by Taub<sup>14</sup> in 2007 focused on evaluating studies that had at least 10 patients, a clear statement of purpose, acne severity, patient selection, follow-up evaluations, previous and concurrent medications, treatment parameters, methods for evaluating results, and adverse effects. Studies involving each modality of treatment were categorized into randomized controlled, controlled studies, or case series. Taub noted the most advanced and promising studies based on clinical results, but not necessarily factoring in study design, involved the use of 3 device types: (1) red and blue monochromatic light delivered by fluorescent tubes or light emitting diodes, (2) the 1450 nm infrared laser, and (3) photodynamic therapy using aminolevulinic and methylaminolevulinic acid as a photosensitizing agent, followed by irradiation with blue light, red light, and the 595 nm pulsed dye laser.

The aforementioned articles collectively noted the promise in the future of device treatment for acne, and several of the authors discussed the lack of quality studies (today, more commonly known as evidence-based studies) to more definitively validate laser/light device treatment for acne. Conceptually, the practice of evidence-based medicine intends to integrate the current best-available evidence from systematic research with clinical experience when making decisions about health care of individual patients.<sup>16</sup> With regards to the medical treatment of acne, evidence-based reviews have been previously undertaken.<sup>17</sup> The Cochrane reviewers concluded that minocycline is likely to be an effective treatment for moderate acne vulgaris, but their review found no reliable randomized clinical trial evidence to justify its continued use first-line, especially given the price differential and the con-



**Figure 3** The authors' approach to laser/light device treatment of acne, depending on predominance of acne lesion type and distribution on the face.

cerns that still remain about its safety. Its efficacy relative to other acne therapies could not be reliably determined due to the poor methodological quality of the trials and lack of consistent choice of outcome measures.<sup>17</sup>

Along these lines, Haedersdal and coworkers recently published the first evidenced based review of lasers, light sources, and photodynamic therapy in the treatment of acne.<sup>18</sup> Their results will be summarized in the following paragraphs, with an emphasis on study design rather than mechanisms of action. The authors set the tone by noting that although many studies have been published on optical treatments of acne, and clinical results seem impressive, these studies are of varying quality, and several clinical trials are designed with uncontrolled before-after design, which do not account for the intrinsic volatility of acne.<sup>18</sup>

Haedersdal and coworkers<sup>18</sup> initiated a retrospective review of the PubMed and Cochrane databases from March 2007 with an extensive keyword search comprehensive of laser/light or photodynamic therapy treatment for acne, restricting searches to controlled trials (randomized or not) with a sample size of at least 10 subjects. Each study was evaluated according to study design, randomization procedure (method of generation and concealment of allocation), and blinding of observers. Studies were classified as either randomized-controlled clinical trials (RCTs) or nonrandomized-controlled clinical trials (CTs). All in all, 27 potentially relevant studies were identified, of which 6 were RCTs and 3 were CTs, involving a total of 587 patients.<sup>15,19-36</sup> Study types and subject numbers are summarized in Table 1. (Of note, the authors of this article ran the same search of the MEDLINE and Cochrane databases by using Ovid for the time period of March 2007 until June 2008 found one CT study that compared different treatment pulsing methods utilizing the 1450 nm laser to treat acne<sup>37</sup>).

Haedersdal and coworkers<sup>18</sup> note that the cited studies include important evidence for optical treatments with lasers, light sources, and PDT for acne vulgaris with 16 identified RCTs and 3 nonrandomized CTs. However, most of the studies were of suboptimal methodological quality as the randomization method was mentioned in just 6 of 16 RCTs, only one trial described adequate allocation concealment, and

most studies had many losses to follow-up with no intention-to-treat analyses.

Of all the evidence-based studies evaluated, they found the most substantial evidence for photodynamic therapy (PDT), which in 5 RCTs with red light-activated methyl-aminolevulinic acid-PDT and aminolevulinic-PDT documents a beneficial efficacy on acne of approximately 50% to 60% up to 20 weeks after 1 to 3 treatments. In one of these trials, a prolonged efficacy is found up to 1 year after treatment. Additionally, IPL-assisted PDT seems to be more efficacious than IPL alone.

They concede that a variety of factors may influence the outcome from acne treatments, which are not accounted for in their review. They acknowledge that acne vulgaris is a multifactorial disorder of the pilosebaceous unit with a tendency to intrinsic exacerbations as well as extrinsic factors such as sun exposure, topical moisturizers, and cleansing may influence disease severity. Other confounding factors may be related to the fact that the optimal settings with lasers and IPL devices (eg, wavelength, pulse duration, fluence) remain to be established, as well as individual characteristics (endocrine dysfunction, type and severity of acne, anatomical region) may influence the treatment outcome. Finally, they conclude that it is therefore essential that clinicians continue to develop and improve the promising optical treatments for acne. On the basis of the present best-available evidence, optical treatments with lasers, light sources and PDT possess the potential to improve inflammatory acne on a short-term basis with the most consistent outcomes for PDT. Laser/light treatments for acne should not be promoted to patients as first line therapy.<sup>18</sup>

In summary, patients of all ages afflicted with acne should be afforded swift and effective treatment to prevent physical and psychological sequelae. First-line medical treatments should be initiated once the clinical diagnosis is made. Device treatments which have shown success in controlled clinical trials, such as photodynamic therapy, can be considered as adjuncts in the event that patients fail medical therapy or are slow to respond. This is especially a consideration in those who permanent scarring is a distinct possibility. Consideration should be given to patients with severe acne, whose personal concerns about side effects such as emerging antibiotic resistance or potential depression episodes associated with isotretinoin, preclude them from considering conventional medical therapies.

**Table 1 Study Types and Numbers of Subjects**

Device Classification	Type of Controlled Studies	Total No. Subjects
Pulsed dye laser (585 nm)	2 RCTs	81
KTP (532 nm)	1 RCT	29
Infrared lasers (1320 nm, 1450 nm)	4 RCTs	113
Intense pulsed light with photodynamic therapy	1 RCT, 2 CTs	59
Broad-spectrum light sources (red and/or blue light)	3 RCTs, 1 CT	194
Photodynamic therapy (with aminolevulinic acid or methyl-aminolevulinic acid)	5 RCT	114

## References

- Collier CN, Harper CJ, Cantrell WC, et al: The prevalence of acne in adults 20 years and older. *J Am Acad Dermatol* 58:56-59, 2007
- Lasek RJ, Chren MM: Acne vulgaris and the quality of life of adult dermatology patients. *Arch Dermatol* 134:454-458, 1998
- Cunliffe WJ: Acne and unemployment. *Br J Dermatol* 115:386, 1986
- Girman CJ, Hartmaier S, Thiboutot D, et al: Evaluating health-related quality of life in patients with facial acne: Development of a self-administered questionnaire for clinical trials. *Qual Life Res* 5:481-490, 1996
- Cordain L, Lindeberg S, Hurtado M, et al: Acne vulgaris. A disease of western civilization. *Arch Dermatol* 138:1584-1590, 2002
- Eady AE, Cove JH, Layton AM: Is Antibiotic resistance in cutaneous propionibacteria clinically relevant? Implications of resistance for acne patients and prescribers. *Am J Clin Dermatol* 4:813-831, 2003

7. Mills OH, Kligman AM: Ultraviolet phototherapy and photochemotherapy of acne vulgaris. *Arch Dermatol* 98:221-223, 1978
8. Mills OH, Porte M, Kligman AM: Enhancement of comedogenic substances by UV radiation. *Br J Dermatol* 98:145-150, 1978
9. Mariwalla K, Rohrer TE: Use of lasers and light-based therapies for treatment of acne vulgaris. *Lasers Surg Med* 37:333-342, 2005
10. Omi T, Munavalli GS, Kawana S, et al: Ultrastructural evidence for thermal injury to pilosebaceous units during the treatment of acne using photopneumatic (PPX) therapy. *J Cosmet Laser Ther* 10:7-11, 2008
11. Shamban AT, Enokibori M, Narurkar V, et al: Photopneumatic technology for the treatment of acne vulgaris. *J Drugs Dermatol* 7:139-145, 2008
12. Ortiz A, Van Vliet M, Lask G, et al: A review of lasers and light sources in the treatment of acne vulgaris. *J Cosmet Laser Ther* 7:69-75, 2005
13. Ross EV: Optical treatments for acne. *Dermatol Ther* 18:253-266, 2005
14. Taub AF: Procedural treatments for acne vulgaris. *Dermatol Surg* 33:1005-1026, 2007
15. Orringer JS, Kang S, Hamilton T, et al: Treatment of acne vulgaris with a pulsed dye laser: A randomized controlled trial. *JAMA* 291:2834-2839, 2003
16. Sackett DL, Rosenberg WMC, Gray JAM, et al: Evidence based medicine: What it is and what it isn't. *BMJ* 312:71-72, 1996
17. Garner SE, Eady EA, Popescu C, et al: Minocycline for acne vulgaris: Efficacy and safety. *Cochrane Database Syst Rev* CD002086, 2003
18. Haedersdal M, Togsverd-Bo K, Wulf HC: Evidence-based review of lasers, light sources and photodynamic therapy in the treatment of acne vulgaris. *J Eur Acad Dermatol Venereol* 22:267-278, 2008
19. Yeung CK, Shek SY, Bjerring P, et al: A comparative study of intense pulsed light alone and its combination with photodynamic therapy for the treatment of facial acne in Asian skin. *Lasers Surg Med* 39:1-6, 2007
20. Seaton ED, Charakida A, Mouser PE, et al: Pulsed-dye laser treatment for inflammatory acne vulgaris: randomised controlled trial. *Lancet* 362:1347-1352, 2003
21. Baugh WP, Kucaba WD: Nonablative phototherapy for acne vulgaris using the KTP 532 nm laser. *Dermatol Surg* 31:1290-1295, 2005
22. Orringer JS, Kang S, Maier L, et al: A randomized, controlled, split-face clinical trial of 1320-nm Nd: YAG laser therapy in the treatment of acne vulgaris. *J Am Acad Dermatol* 56:432-438, 2007
23. Jih MH, Friedman PM, Goldberg LH, et al: The 1450-nm diode laser for facial inflammatory acne vulgaris: Dose-response and 12-month follow-up study. *J Am Acad Dermatol* 55:80-87, 2006
24. Wang SQ, Counters JT, Flor ME, et al: Treatment of inflammatory facial acne with the 1,450 nm diode laser alone versus microdermabrasion plus the 1,450 nm laser: A randomized, split-face trial. *Dermatol Surg* 32:249-254, 2006
25. Paithankar DY, Ross EV, Saleh BA, et al: Acne treatment with a 1450 nm wavelength laser and cryogen spray cooling. *Lasers Surg Med* 31:106-114, 2002
26. Gold MH, Rao J, Goldman MP, et al: A multicenter clinical evaluation of the treatment of mild to moderate inflammatory acne vulgaris of the face with visible blue light in comparison to topical 1% clindamycin antibiotic solution. *J Drugs Dermatol* 4:64-70, 2005
27. Tzung T-Y, Wu K-H, Huang M-L: Blue light phototherapy in the treatment of acne. *Photodermatol Photoimmunol Photomed* 20:266-269, 2004
28. Papageorgiou P, Katsambas A, Chu A: Phototherapy with blue (415 nm) and red (660 nm) light in the treatment of acne vulgaris. *Br J Dermatol* 142:973-978, 2000
29. Hörfelt C, Funk J, Frohm-Nilsson M, et al: Topical methyl aminolevulinate photodynamic therapy for treatment of facial acne vulgaris: results of a randomized, controlled study. *Br J Dermatol* 155:608-613, 2006
30. Wiegell SR, Wulf HC: Photodynamic therapy of acne vulgaris using methyl aminolevulinate: A blinded, randomized, controlled trial. *Br J Dermatol* 154:969-976, 2006.
31. Wiegell SR, Wulf HC: Photodynamic therapy of acne vulgaris using 5-aminolevulinic acid versus methyl aminolevulinate. *J Am Acad Dermatol* 54:647-651, 2006
32. Pollock B, Turner D, Stringer MR, et al: Topical aminolevulinic acid-photodynamic therapy for the treatment of acne vulgaris: A study of clinical efficacy and mechanism of action. *Br J Dermatol* 151:616-622, 2004
33. Hongcharu W, Taylor CR, Chang Y, et al: Topical ALA-photodynamic therapy for the treatment of acne vulgaris. *J Invest Dermatol* 115:183-192, 2000
34. Rojanamatin J, Choawawanich P: Treatment of inflammatory facial acne vulgaris with intense pulsed light and short contact of topical 5-aminolevulinic acid: A pilot study. *Dermatol Surg* 32:991-997, 2006
35. Santos MAV, Belo VG, Santos G: Effectiveness of photodynamic therapy with topical 5-aminolevulinic acid and intense pulsed light versus intense pulsed light alone in the treatment of acne vulgaris: Comparative study. *Dermatol Surg* 31:910-914, 2005
36. Goldman MP, Boyce SM: A single-center study of aminolevulinic acid and 417 nm photodynamic therapy in the treatment of moderate to severe acne vulgaris. *J Drugs Dermatol* 2:393-396, 2003
37. Uebelhoefer NS, Bogle MA, Dover JS, et al: Comparison of stacked pulses versus double-pass treatments of facial acne with a 1,450-nm laser. *Dermatol Surg* 33:552-559, 2007