

Rejuvenation with photodynamic therapy: clinical improvement, collagen and elastic fiber analysis

Rejuvenescimento com terapia

fotodinâmica: melhora clínica e análise do colágeno e das fibras

ABSTRACT

Introduction: Photodynamic therapy is a promising treatment for moderate photoaging.

Objective: To evaluate the clinical and histological changes in elastin and collagen fibers following photodynamic therapy with 5-aminolevulinic acid.

Methods: Female patients received three sessions of photodynamic therapy with 5-aminolevulinic acid, irradiated by a red-light (630 nm) light-emitting diode every 2 weeks. We evaluated the clinical improvement of photoaging, and also the increase in collagen and elastic dermal tissue by histomorphometry, using Picrosirius and Weigert-oxone staining, before treatment, 24 h after the first session, and 21 days after the third session. The results were evaluated using a semiquantitative method according to the following scores: 0 = absence of reaction, 0.5 = very weak reaction, 1.0 = minor reaction, 2.0 = moderate reaction, 3.0 = intense reaction.

Results: Thirteen patients participated in the study. When assessed 21 days after the last treatment, 12 patients showed improvement in photoaging, especially regarding skin color and texture, clearing of solar melanosis, regression of actinic keratosis, and improvement of flaccidity. In the histomorphometric evaluation, an increase in collagen and elastic fiber tissue was observed. These outcomes have been statistically proven.

Conclusions: Photodynamic therapy with 5-aminolevulinic acid, associated with red light, was clinically and histopathologically proven to be an effective treatment for clinical photoaging.

Keywords: skin aging; photochemotherapy; aminolevulinic acid; collagen; elastic tissue.

RESUMO

Introdução: Atualmente a terapia fotodinâmica é considerada uma modalidade terapêutica com resultados promissores no tratamento do fotoenvelhecimento moderado.

Objetivo: Avaliação dos resultados clínicos e das mudanças histológicas no colágeno e nas fibras elásticas após a realização da terapia fotodinâmica com ácido 5-aminolevulinico.

Métodos: Pacientes do sexo feminino foram submetidas a três sessões a cada duas semanas, de terapia fotodinâmica com ácido 5-aminolevulinico irradiado por luz vermelha de Diodos Emissores de Luz de 630 nm. Foi avaliada a melhora clínica do fotoenvelhecimento através de método semi-quantitativo usando os escores: 0 = ausência de reação; 0.5 = reação muito fraca; 1.0 = reação discreta; 2.0 = reação moderada; 3.0 = reação intensa. As mudanças do colágeno e do tecido elástico dérmico corados respectivamente pelos métodos de Picrosirius e de Weigert-oxone, foram avaliadas por histomorfometria no período prévio ao procedimento, 24 horas após a primeira sessão e 21 dias após a terceira sessão.

Resultados: Treze pacientes foram incluídas nesse estudo analítico e prospectivo. Na avaliação clínica, 21 dias após o último tratamento, 12 pacientes apresentaram melhora do fotoenvelhecimento, especialmente no que diz respeito à cor e textura da pele, clareamento de melanoses solares, regressão de queratoses actínicas, e melhora da flacidez. Na avaliação histomorfométrica, ocorreu aumento de colágeno e fibras elásticas. Estes dados foram estatisticamente comprovados.

Conclusão: A terapia fotodinâmica com ácido 5-aminolevulinico associado à luz vermelha foi considerada eficaz no tratamento do fotoenvelhecimento após avaliações clínicas e histológicas.

Palavras-chave: envelhecimento da pele; terapia fotodinâmica; ácido aminolevulinico; colágeno; tecido elástico.

Original article

Authors:

Ana Carolina Ferolla¹
Bertha M. Tamura²
Luís Carlos Cucé³

¹ PhD in Sciences from the University of São Paulo Medical School (FMUSP) - São Paulo (SP), Brasil

² PhD in Dermatology from the University of São Paulo Medical School (FMUSP) - São Paulo (SP), Brasil

³ Post-doctoral degree and PhD in Dermatology from the University of São Paulo Medical School (FMUSP) - São Paulo (SP), Brasil

Correspondence:

Dra. Ana Carolina Ferolla
Rua Afonso Brás, 473 Conjunto 63
Vila Nova Conceição
04511 011 São Paulo SP

Received on: 05/11/2009
Approved on: 01/03/2010

This study was conducted at the Dermatology Department of the University Hospital, University of São Paulo Medical School (FMUSP) - São Paulo (SP), Brazil

Conflicts of interest: none
Financial support: none

INTRODUCTION

The characteristic changes induced by photoaging are: a decrease in fibroblasts; elastic tissue hyperplasia with increased, thick, coiled, and entangled elastic fibers; and thinned, flattened collagen fibers. There is a decrease in type I and III collagen protein precursors and an increase in glycosaminoglycans (GAGs), which are typically deposited in the elastotic tissue rather than among collagen and elastic fibers.^{1,2} Photodynamic therapy (PDT) has been considered as a treatment option for photoaging; and, 5-aminolevulinic acid (ALA) and red light (630 nm) from a light-emitting diode (LED) induce an increase in production of matrix metalloproteinase 1 and 3 (MMP1; MMP3) in cultures of human dermal fibroblasts. A reduction in the expression of type I collagen mRNA also occurs, while type III collagen mRNA remains quantitatively unchanged.³ Keratinocytes are PDT targets, as ALA penetrates keratinized tissues and only lightly penetrates mesenchymal tissues. Thus, it is proposed that the induction of collagen degradation by metalloproteinases occurs via keratinocytes.^{3,4}

OBJECTIVE

The objective of this study was to evaluate the clinical and histological changes in elastin and collagen fibers following the use of topical ALA with PDT (ALA-PDT).

METHODS

This was an open, prospective and analytical study. Recruitment criteria included: female patients with phototype I–IV,⁵ with the presence of photoaging skin type I–IV, according to the Glogau classification of photoaging.⁶ Exclusion criteria were the use, within the last month, of an abrasive method or keratolytic substance, recent systemic diseases and surgery, history of keloid formation and/or hypertrophic scars, skin cancer, a family history of melanoma, and the use of photosensitizing or immunosuppressant medications.

The study was conducted at the Dermatology Department of the Hospital das Clínicas, Faculty of Medicine, University of São Paulo under the approval of the Ethics and Research Committee of that institution. All patients signed a consent form, were photographed (digital camera: Canon PowerShot A80, 4.0 megapixels), and biopsied at the right preauricular region, which was fully measured and divided into three distinct areas. A biopsy was performed for each area and sent for anatomical and pathological analysis. In the first area, the biopsy was performed before the procedure; in the second, it was performed 24 h following the first session; and in the third, 21 days after the third session.

Hence, three PDT sessions were performed every 15 days. The face was cleaned beforehand with alcohol, and then a 20% topical solution of ALA (Levulan® Kerastick™, Dusa Pharmaceuticals, Inc., Wilmington, Massachusetts, USA) was homogeneously applied. Two hours later we irradiated each hemiface for 10 min with a 630 nm wavelength LED device with an exit intensity of 3,100 mW/cm², optical intensity of 100 mW/cm², and an active surface of 40 x 80 mm. Patients were told about potential side effects, photoprotection, the use of chemical products without prior permission, return visits on scheduled dates, and about the importance of not removing skin in case of scaling.

Patients were clinically evaluated before and after the PDT sessions and any changes were classified using a semiquantitative method, according to the following scores: 0 = absence of reaction; 0.5 = very weak reaction; 1.0 = minor reaction; 2.0 = moderate reaction; 3.0 = intense reaction.

Dermal collagen was stained using a 0.2% Picosirius red stain (Sirius Red, Direct Red 80; C. I. 35780; Aldrich, Milwaukee, Wisconsin, USA). In order to evaluate the mature elastic, elauninic and oxytalan fibers, tissue slides were stained with Weigert's fuchsin-resorcin (2KHSO5. KHSO4. K2SO4,

Table 1 – Clinical results obtained after treatment

Patient	Degree of photoaging	Photoaging improvement after PDT-ALA	Texture/Color	Melanosis	Keratosis	Superficial wrinkles
1	Glogau III	Moderate	Improvement	Improvement	–	–
2	Glogau IV	Important	Improvement	Improvement	Regression	Improvement
3	Glogau IV	Minor	Improvement	Improvement	–	–
4	Glogau III	Moderate	Improvement	Improvement	–	–
5	Glogau III	Important	Improvement	Improvement	Regression	–
6	Glogau IV	Minor	Improvement	Improvement	Partial regression	Improvement
7	Glogau II	Moderate	Improvement	Improvement	–	Improvement
8	Glogau II	Minor	Improvement	–	–	–
9	Glogau III	Important	Improvement	Improvement	Regression	Improvement
10	Glogau IV	Unchanged	Absent	Unchanged	–	–
11	Glogau IV	Minor	Improvement	Improvement	–	–
12	Glogau III	Important	Improvement	Improvement	–	Improvement
13	Glogau III	Moderate	Improvement	Improvement	–	–

Table 2 – Skin flaccidity results after treatment

Patient	Degree of photoaging	Flaccidity	Nasogenian fold	Mandibular region	Lower lid region
1	Glogau III	Improvement	+	+	-
2	Glogau IV	Improvement	-	+	-
3	Glogau IV	Improvement	-	+	-
4	Glogau III	Improvement	-	+	-
5	Glogau III	Improvement	-	+	-
6	Glogau IV	Improvement	-	+	-
7	Glogau II	Improvement	-	+	+
8	Glogau II	Improvement	+	-	+
9	Glogau III	Improvement	-	+	+
10	Glogau IV	Unchanged	-	-	-
11	Glogau IV	Improvement	-	+	-
12	Glogau III	Improvement	-	+	+
13	Glogau III	Improvement	-	-	+

DuPont Co.). Histomorphometric data, relative to the collagen area fraction and elastic fibers, were obtained with the aid of an image analyzer system (Kontron Electronic 300, ZEISS, Germany) and analyzed using descriptive statistics (mean, standard deviation, minimum and maximum values, and median).

The values resulting from a single treatment before and after PDT were subjected to a normality test. The pairwise t-test was chosen to analyze dermal collagen variation at three distinct time points for the same patient (before treatment, 24 h after treatment, and 21 days after the third treatment), if the results showed a regular distribution. When data were within a normal curve, we used analysis of variance (ANOVA) to assess whether the means of the three groups could be replaced by a single factor and whether the null hypothesis did not apply in the studied population. When data did not show a regular distribution, the Wilcoxon's signed-rank test was performed to see whether a single treatment for the same individual was significant. Otherwise, we also used the ANOVA on ranks or the Kruskal-Wallis test to compare the median of the three time points. To assess the correlation between clinical improvement intensity and the gain in collagen and elastic fibers in the dermis after treatment, linear regression testing was used. Statistical tests were performed using SigmaStat software (Jandel Scientific, California, USA), with a significance level of $p < 0.05$.

RESULTS

Thirteen patients took part in the study, aged 50–78 years (mean, 64 years). According to the Glogau classification of photoaging groups, six patients presented with photoaging grade III (46.15%), five presented with grade IV (38.46%), and two presented with grade II (15.38%). As for the phototypes involved, two patients presented with phototype I (15.38%), five presented with phototype II (38.46%), five presented with phototype III (38.46%), and one presented with phototype IV (7.69%).

Regarding patients' clinical evaluations, the following were observed: 12 patients (92.30%) showed clinical photoaging improvement and only one patient (7.69%) was unchanged. Of the 12 patients whose condition had improved, five (41.66%) showed major improvement, four (30.76%) moderate improvement, and three (23.09%) discrete improvement. Superficial wrinkles were mildly improved in five patients (38.46%), particularly on the forehead and in the periocular area (Figures 1A and 1B), whereas no change in deep wrinkles was observed. Twelve patients (92.30%) showed improvement of skin flaccidity, and one patient (7.69%) remained unchanged. Five patients (41.66%)

showed improvement of flaccidity, particularly in the lower lid region, two patients (16.66%) on the nasolabial fold, and 10 (83.33%) in the mandibular region. All patients presented with skin color and texture change. The skin appeared yellowish, opaque, and uneven in texture, with both oily and dry areas. Twelve patients (92.30%) showed improvement in skin color and texture and only one patient (7.69%) remained unchanged. Two patients (15.38%) with ephelides had only a partial clearing of lesions, and four patients (30.76%) with melasma presented with no change in the condition. Of the 12 patients (92.30%) with melanoses, 11 (91.66%) displayed only a partial clearing of lesions and one patient (8.33%) exhibited no change. Of the four patients (30.76%) who presented lesions with a clinical diagnosis of actinic keratosis, only one (25%) retained a residual lesion on the dorsum of the nose. The other three patients (75%) had a total regression of lesions (see Tables 1 and 2).

The patients showed erythema of mild to significant intensity, edema mainly on the lower lid, pricking, discrete pruritus, and mild to moderate scaling. These reactions varied among patients and were different between the three sessions. For most patients, the duration was about 3–5 days. Specifically, these effects lasted at least 2 days and at most 10 days, with a mean duration of 6 days. Two patients developed Herpes Simplex

Virus lesions, one patient after the first session and the other after the second; only one patient reported 24-hour photosensitivity on exposure to natural sunlight after the third session.

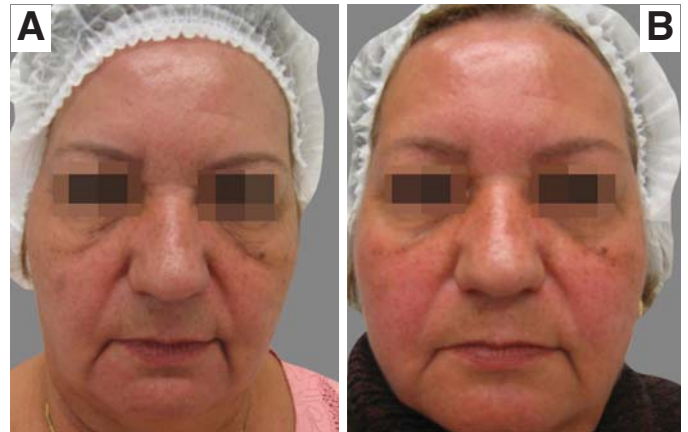The results of the histological analysis and of the collagen and elastic fiber histomorphometry were evaluated in only 12 patients, due to technical problems with the biopsies. In the majority of cases, pretreatment biopsies showed epidermis with dermal papilla rectification and keratinocytes within normal limits. The papillary dermis showed variable quantities of solar elastosis and areas with highly reduced collagen fibers. In the papillary dermis, collagen fibers showed variable thickness and reduced size, with a disorganized distribution.

Biopsies performed 24 h after treatment showed spongiosis and variable intracellular edema. Occasionally, vacuolization in the basal layer was observed. There were also instances of edema interspersing between collagen fibers at the papillary dermis. By the end of treatment, the biopsies still showed epidermis with rectification and keratinocytes within normal limits. The basal layer was preserved. Collagen fibers increased at the papillary dermis, and they were organized and parallel to the epidermis.

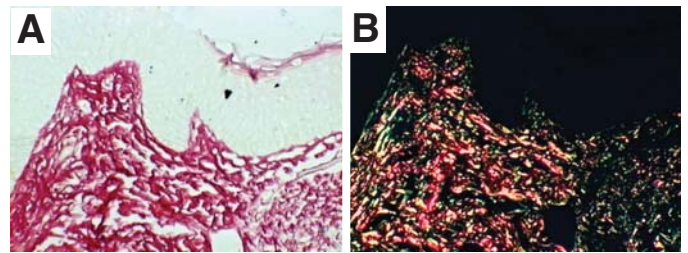
Dermal collagen and elastin were evaluated histomorphometrically using an image analyzer system. We observed that the dermis in the pretreatment skin biopsies had a small amount of short and disorganized collagen fibers. Figures 2A and 2B show the collagen fibers stained using the Picrosirius red stain) and the same area observed under polarized light. Figures 3A and 3B show the collagen fibers stained using the Picrosirius red stain and the same area obtained using the image analyzer system, The collagen area fraction of the dermis from skin biopsies pretreatment, 24 h after treatment, and post-treatment (21 days after the third session) was $22.8\% \pm 6.22\%$, $18.8\% \pm 4.13\%$, and $38.3\% \pm 2.65\%$, respectively. Table 3 and Graph 1 show the mean, standard deviation, maximum and minimum values, and median value of the collagen area fraction from the skin biopsies. By

comparing the pretreatment, 24 h after treatment, and post-treatment values using a pairwise t-test, a significant difference in collagen percentages was observed, with a reduction of collagen percentage 24 h after treatment ($t = -3.189$ with 11 GL, $p = 0.009$). The pre- and post-treatment, and the 24 h after and post-treatment analysis revealed a significant increase in collagen percentage ($t = 6.112$ with GL, $p = 0.001$) and ($t = 7.880$ with 10 GL, $p \leq 0.001$), respectively. By comparing the three time points studied – pretreatment, 24 h after treatment, and post-treatment – of an individual’s treatment using the Kruskal–Wallis test, a significant difference was observed ($H = 19.106$ with 2GL, $p \leq 0.001$). As post hoc analysis, the Dunn’s test was applied, which revealed a highly significant difference in collagen percentage before and after treatment, with an increase in collagen post-treatment ($Q = 13.061$, $p < 0.05$).

The pretreatment dermis revealed thick and short elastic fibers, which were sometimes curved and disorganized or distributed in clusters. Distribution among the collagen fibers was non-homogeneous. Figures 4A and 4B show the elastic fibers stained black by the Weigert–oxone technique and the same



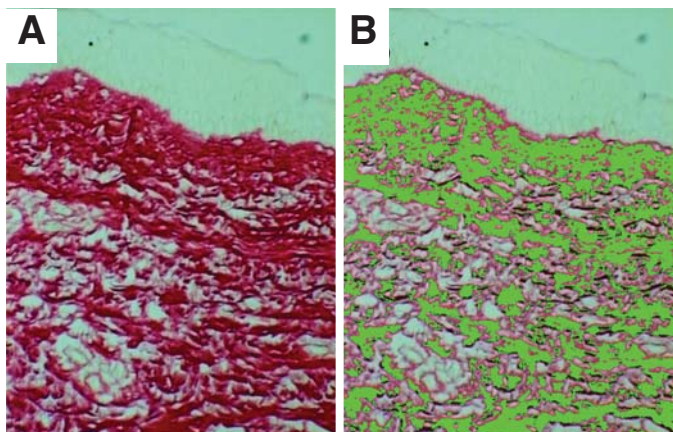
Figures 1A and 1B - Pictures before and 21 days after the third session of PDT-ALA



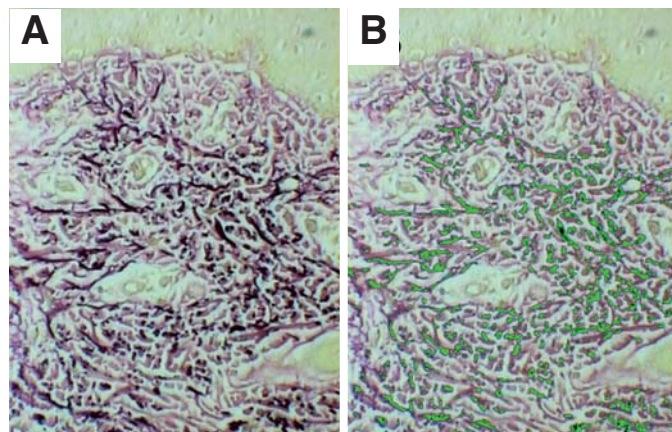
Figures 2A and 2B - Pre-treatment histological specimen (case 4). A: Collagen fibers in the dermis stained red using the Picrosirius method (340x). B: The same histological specimen observed with polarized light, showing short and disorganized collagen fibers (Picrosirius 340x)

histological field labelling by image analyser system. The 24-h post-treatment skin biopsies demonstrated a reduction in elastic fibers due to dermal edema. By the end of the treatment, we observed a higher quantity of elastic fibers, which were longer and parallel to the collagen fibers. Graph 2 displays the mean, standard deviation, maximum and minimum values, and median value of the fractional area of elastic fibers. We compared the pre-treatment, 24 h after treatment, and post-treatment elastin area fraction values using the pairwise t-test; the results were 7.68 ± 2.82 , 5.78 ± 2.49 , and 11.34 ± 4.35 , respectively. By comparing the pre-treatment, 24 h after treatment, and post-treatment percentages of elastic fibers, a significant difference was observed, with a reduction in elastic fiber percentage 24 h post-treatment ($t = -2.581$ with 11 GL, $p = 0.026$). When we applied the pairwise t-test, a significant difference was observed, with an increase in elastic fiber per-

Table 3 – Collagen percentage in the dermis			
Statistic	Collagen % before	collagen % 24h	collagen % Final
Mean	22.8	18.8	38.3
Standard deviation	6.22	4.13	2.65
Maximum	32.68	27.63	52.93
Minimum	12.83	14.20	21.12
Median	22.29	17.64	37.80

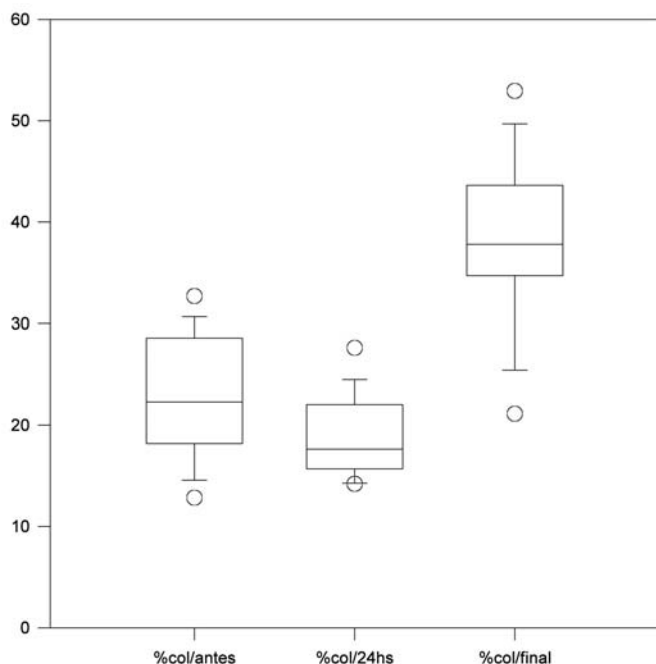


Figures 3A and 3B – Pre-treatment histological specimen (case 7). A: Collagen fibers in the dermis stained in red using the Picrosirius method (340x). B: The same histological specimen with collagen fibers labeled by Image Analyzer System (340x)



Figures 4A and 4B – Pre-treatment histological specimen. A: Elastic fibers in the dermis with Weigert-oxone staining (340x). B: The same histological specimen with elastic fibers characterized by the Image Analyzer System (340x)

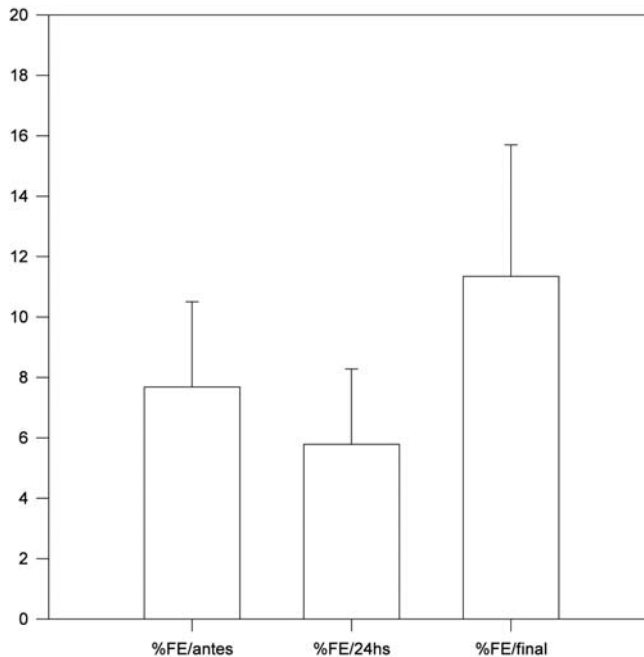
% colágeno derme



Graph 1 – Collagen percentage of the dermis before, 24 hours after, and at the end of treatment

centage by the end of treatment ($t = 4.001$ with 11GL, $p = 0.002$). By comparing the three time points studied – pre-treatment, 24 h after treatment, and post-treatment – of an individual’s treatment, using a parametric ANOVA, a significant difference was revealed ($F = 8.695$, $p < 0.001$). As a post hoc test, Tukey’s method for multiple comparisons was applied, which revealed a highly significant difference in elastic fiber percentages before and after treatment, with an increase in elastic fibers post-treatment ($Q = 3.82$; $p < 0.05$).

% FE derme



Graph 2 – Elastic fibers percentage of the dermis before, 24 hours after, and at the end of treatment

DISCUSSION

Photoaging improvement following PDT as documented in this study was similar to the results described by several authors.⁷⁻¹⁰ Nestor et al.¹¹ report excellent results using ALA-PDT for rejuvenation with an improvement percentage of 92%, according to the investigators’ evaluation, and 94% according to patients’ evaluation.

The color and texture improvement obtained in the patients in this study (92.30%) slightly exceeded the data reported by other authors, which was between 25%10 and 75%.6 There are no concrete data regarding flaccidity in the literature.

While moderate or discrete, an improvement of flaccidity occurred in 92.30% of patients, with 41.66% presenting with improvement in the lower lid, 16.66% in the nasolabial fold, and 83.33% in the mandibular region, with a resulting improvement in facial contour. This observation is important when compared with other treatments since we can hardly improve skin flaccidity with a non-invasive treatment.

Solar melanosis showed clearing, although partial (91.66%), with the same occurring with ephelides present in two (15.38%) patients. The melasma present in four (30.76%) patients remained unchanged. Four patients (30.76%) presented with lesions with a clinical diagnosis of actinic keratosis; 21 days after the third session, 75% of these patients showed a complete remission of lesions. The percentage of improvement in actinic keratosis in the treatment of photoaging that is reported in the literature ranges from 75 to 90%, with faster improvement on the face and scalp and slower changes on the extremities and trunk.^{7,9}

The most commonly reported side effects in this study were: mild to intense erythema; edema, particularly in the lower lid; pricking; discrete pruritus; and mild to moderate scaling.^{10, 12, 13} In the study group, we could not make a correlation between erythema and photoaging improvement. Only one patient (7.69%) presented with long-term photosensitivity due to the exposure to sunlight the day after PDT treatment. We observed that most of the patients reported a tolerable burning sensation immediately after exposure, lasting approximately 24–48 h, although accompanied by major edema – not related to the patient's clinical complaint of pain or pricking. The edema was more pronounced on the lower lid and lasted approximately 3 days.¹⁴

Bacterial infections are uncommon in this type of procedure, with viral infections occurring in susceptible individuals.¹⁰ Two patients (15.38%) exhibited a clinical condition similar to that of herpes simplex, one patient presented with an erythematous, painful papulovesicular lesion in the chin region 3 days after the procedure, and the other patient presented with oral vesicles at the second session. Since no patient used antiviral prophylaxis prior to therapy, we suggest that such prophylaxis may be indicated for patients with a history of herpes simplex. No scarring, hyperchromias, or hypochromias were observed.

As observed with the aid of staining methods – Picrosirius for collagen and Weigert-oxone for elastic tissue – edema, together with fiber disorganization occurring with the procedure, may lead to a decrease in collagen and elastic fiber percentage (fraction/area) after 24 h. However, skin biopsies carried out 21 days after the third treatment session showed an increase in collagen in the papillary dermis, parallel organization of these fibers with respect to the epidermis, and an increase in the number of elastic fibers, which were longer and parallel to the collagen fibers. This subsequent increase may be explained by the time required for stimulating elastic fiber reorganization and collagen synthesis.

CONCLUSIONS

This study of photoaged human skin has demonstrated that three ALA-PDT sessions with red light (630 nm) at 15-day intervals, resulted in the global improvement of photoaging and cutaneous color,

texture, and flaccidity (92.30%), accompanied by a good level of tolerability. Partial clearing of melanosis was observed, with melasma remaining unchanged. The procedure proved to be more efficient in low-phototype subjects. ●

REFERÊNCIAS

1. Lever WF. *Histopatologia da pele* 7a ed. São Paulo: Editora Manole; 1991. p. 269-70.
2. Azulay MM. Revisão científica e consultoria. In: Draelos ZD, editor. *Cosmecêuticos*. Rio de Janeiro: Elsevier, 2006. pp.129-134.
3. Karrer S, Bosserhoff AK, Weiderer P, Landthaler M, Szeimies R-M. Influence of 5-aminolevulinic acid and red light on collagen metabolism of human dermal fibroblasts. *J Invest Dermatol*. 2003;120:325-31.
4. Karrer S, Bosserhoff AK, Weiderer P, Landthaler M, Szeimies R-M. Keratinocyte-derived cytokines after photodynamic therapy and their paracrine induction of matrix metalloproteinases in fibroblasts. *Br J Dermatol*. 2004;151(4):776-83.
5. Fitzpatrick TB. The validity and practicability of sunreactive skin types I through VI. *Arch Dermatol*. 1988;124(6):869-71.
6. Glogau RG. Chemical peeling and aging skin. *J Geriatric Dermatol*. 1994;2(1):30-5.
7. Ruiz-Rodriguez R, Alvarez JG, Jaén P, Acevedo A, Córdoba S. Photodynamic therapy with 5-aminolevulinic acid for recalcitrant familial benign pemphigus (Hailey-Hailey disease). *J Am Acad Dermatol*. 2002;47(5):740-2.
8. Alster T, Hirsch R. Single-pass CO₂ laser skin resurfacing of light and dark skin: extended experience with 52 patients. *J Cosmet Laser Ther*. 2003;5(1):39-42.
9. Gold MH, Goldman MP. 5-aminolevulinic acid photodynamic therapy: where we have been and where we are going. *Dermatol Surg*. 2004;30(8):1077-84.
10. Alam M, Dover JS. Treatment of photoaging with topical aminolevulinic acid and light. *Skin Therapy Lett*. 2004;9(10):7-9.
11. Nestor MS, Gold MH, Kauvar ANB, Taub AF, Geronemus RG, Ritvo EC, et al. The use of photodynamic therapy in dermatology: results of a consensus conference. *J Drugs Dermatol*. 2006;5(2):140-54.
12. Key DJ. Aminolevulinic acid-pulsed dye laser photodynamic therapy for the treatment of photoaging. *Cosmet Dermatol*. 2005;18:31-6.
13. Tosca AD, Balas CJ, Stefanidou MP, Katsantonis JC, Georgiou SK, Tzardi MN. Photodynamic treatment of skin malignancies with aminolevulinic acid. Emphasis on anatomical observations and in vivo erythema visual assessment. *Dermatol Surg*. 1996;22:929-34.
14. Kennedy JC, Pottier RH, Pross DC. Photodynamic therapy with endogenous protoporphyrin IX: basic principles and present clinical experience. *J Photochem Photobiol B*. 1990;6:143-8.